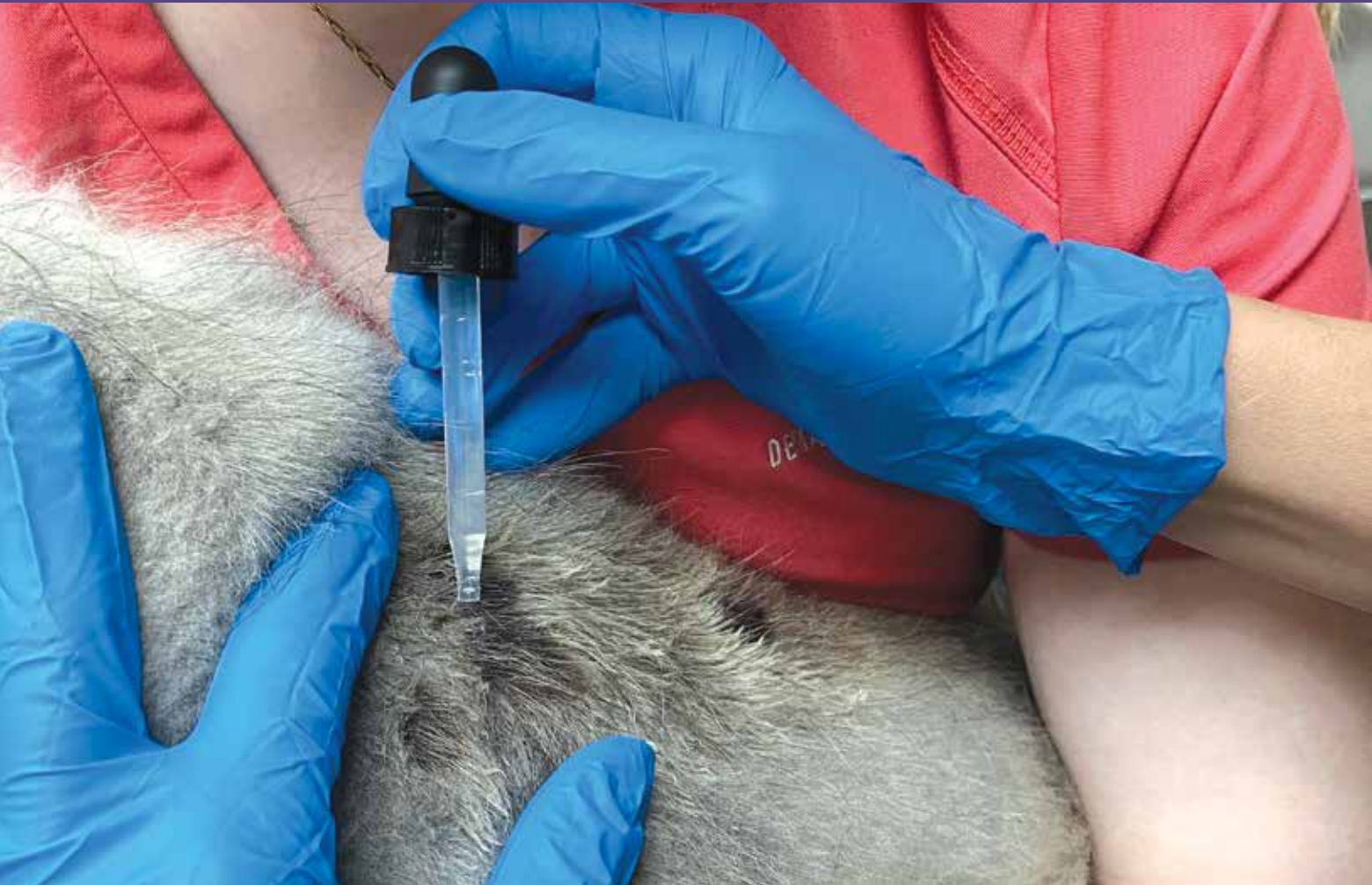



PESTS AND PARASITES

Skin Scrapings for Identifying Parasites

Shilo Anderson, LVT, VTS (Dermatology)
Dermatology for Animals, Salt Lake City, Utah

Abstract

Ectoparasites are an important differential in animals presenting to the clinic with skin problems. The veterinary nurse is commonly trained to obtain samples using a variety of techniques—including superficial and deep skin scrapings, tape impressions, hair plucks, and coat combing—and examine those samples under the microscope. The veterinary nurse plays a crucial role in client communication, such as informing clients on sample collection and what the veterinarian is looking for.



Take-Home Points

- Different parasites live at different layers of the skin; therefore, collecting samples from the surface, superficial layer (epidermis), and deeper layer (dermis) of the skin is recommended.
- When examining samples for ectoparasites under the microscope, it is helpful to close the condenser diaphragm all the way down, which allows for maximum contrast and visualization of the parasite within the debris.
- Surface layer sampling using flea combs, stiff brushes, and transparent tape can be used to collect and identify lice, fleas, and surface-dwelling mites such as *Cheyletiella* species and *Otodectes cynotis* (ear mite).
- Superficial skin scrapings are useful in collecting surface-dwelling mites, as well as the burrowing mites *Sarcoptes scabiei* (canine scabies) and *Notoedres cati* (feline scabies).
- Deep skin scrapings are beneficial in ruling out and diagnosing *Demodex* species (demodicosis).
- For superficial and deep skin scrapes, a dulled #10 or #20 blade works well due to the curvature of these blades. This allows for scooping up the sample easily and also helps minimize the risk of tearing or cutting the skin.
- The veterinary nurse should communicate with clients regarding the how and why of obtaining samples.

Skin scraping and other sampling techniques for ectoparasites are simple diagnostics that should be performed with any patient presenting with skin disease. Ectoparasites are a common problem in pets, and these patients present to the veterinary clinic for a variety of client concerns, including pruritus, alopecia, and scaling. Parasites are an important differential in all animals presenting with skin problems and should be confirmed or eliminated in the early stages of the case workup.

It is important that clients know what to expect during the examination, and the veterinary nurse plays a crucial role in client education, satisfaction, and compliance. The veterinary nurse is commonly trained to obtain samples from patients and to examine those samples under the microscope. In-house microscopic diagnostics such as skin scrapes, cytology, and trichograms are common baseline tests for the workup of dermatologic conditions that can be quickly performed and provide valuable information. Keeping the client informed of how these tests are taken and what the veterinarian is looking for can assist with client understanding and should be discussed with the client before or during the sample collection.

There are a variety of sample-collecting techniques, including superficial skin scrapings, deep skin scrapings, tape impressions, hair plucks, and coat combing, that can be used to identify ectoparasites. The small animal veterinarian is most commonly looking for mites (**BOX 1**), fleas, and lice. The patient

history and physical examination will help the veterinary team determine which parasite may be suspected and therefore which sample collection technique may yield the best results. Different parasites live at different levels of the skin; therefore, collecting samples from the surface, superficial layer (epidermis), and deeper layer (dermis) of the skin is important.

When examining samples for ectoparasites under the microscope, it is helpful to close the condenser

BOX 1

Common Mites

Dogs

- *Sarcoptes scabiei* (scabies)
- *Cheyletiella yasguri* (cheyletiellosis)
- *Otodectes cynotis* (ear mites)
- *Demodex canis*, *Demodex cornei*, *Demodex injai* (demodicosis)

Cats

- *Notoedres cati* (scabies)
- *Cheyletiella blakei* (cheyletiellosis)
- *Otodectes cynotis* (ear mites)
- *Demodex cati*, *Demodex gatoi* (demodicosis)
- *Lynxacarus* species



diaphragm all the way down, which allows for maximum contrast and visualization of the parasite. The slide should be examined with the 4× and 10× objective lenses. The 4× lens allows for a larger field of view, and the 10× lens provides greater magnification.

SURFACE LAYER SAMPLING

Surface layer sampling using flea combs, stiff brushes, transparent tape, and physical scraping can be used to collect and identify lice, fleas, and surface-dwelling mites such as *Cheyletiella* species and *Otodectes cynotis*.

Flea combs and stiff brushes are used to comb the hair coat, focusing on areas of scaling, and the debris collected should be placed on a dark background. Parasites may be viewed macroscopically or with a handheld lens. If flea feces are suspected, a white background that is moistened would be more effective at visualizing the reddish-brown staining that is seen due to the partly digested blood in flea feces. The material collected by the combing can also be transferred to a microscope slide with mineral oil and examined under the microscope.

Adhesive, transparent tape (a tape impression) can be used to remove the outer layers of the stratum corneum with attached ectoparasites and eggs.¹ Tape impressions should be taken from both the distal and proximal hair shafts. Part the hairs before collecting the samples. Apply the tape repeatedly to the skin and hair until the tape is no longer sticky and significant debris is stuck to the tape. Apply the tape sticky side down onto a microscope slide and examine with the 4× and 10× objective lenses. There is no need for a coverslip or mineral oil when using the tape impression method. The squeeze-tape technique can be used for *Demodex* mites by pinching the skin to extrude the mites from the hair follicle and applying tape to the pinched area. The process should be repeated a few times before examining the sample under the microscope.

Lice

Lice are divided into 2 suborders—Anoplura (sucking lice) and Mallophaga (chewing lice)—and infestation with lice is referred to as pediculosis. The 2 types that commonly affect dogs are the sucking louse (*Linognathus setosus*) and the chewing louse (*Trichodectes canis*). *Felicola subrostratus* is the cat-biting louse. The operculated white eggs of lice, also known as “nits,” are adhered firmly to the hairs of the host.

Lice are species- and host-specific and are contagious among mammals of the same species. Lice spend their entire life on the host and can be transferred by bodily contact or contaminated fomites.² Lice can only live for a few days off the host; however, eggs that have fallen into the environment can continue to hatch in warm weather over 2 to 3 weeks; therefore, it is important to wash any bedding used by the infected host.

Besides the irritation and intense pruritus that pediculosis can cause, there are other health concerns, depending on which type of lice is identified. Sucking lice can cause anemia and severe debilitation, which can be concerning in young animals.² *T. canis* is a vector for the tapeworm *Dipylidium caninum* and can cause infection in dogs if the infected lice are ingested during grooming.² All in-contact dogs or cats (depending on louse species) should be treated, and the environment and fomites should be cleaned.³

Linognathus setosus

- Dog sucking louse (**FIGURE 1**)
- **Physical characteristics:** Up to 2 mm in length; color ranges from white or tan to brown; long, pointed (tapered) head; 3 pairs of legs³
- **Predilection sites:** Primarily found in the head and neck areas and under the collar
- **Slow moving:** Adults and eggs may be seen within the coat by parting the hair

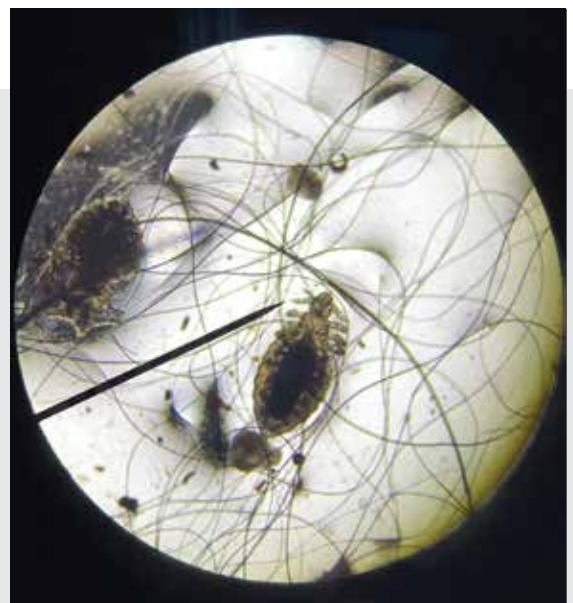

FIGURE 1. Canine sucking louse, *Linognathus setosus*.



Trichodectes canis

- Dog chewing, biting louse
- **Physical characteristics:** 1 to 2 mm in length; yellowish with dark markings; broad head with short, 3-segmented antennae; 3 pairs of legs
- **Predilection sites:** Head, neck, and tail
- **Faster moving than the sucking louse:** Adults and eggs may be seen within the coat by parting the hair

Felicola subrostratus

- Cat chewing, biting louse
- **Physical characteristics:** 1 to 1.5 mm in length; beige or yellow in color; triangular, pointed head; 3 pairs of legs³
- **Predilection sites:** Face, back, and pinnae

Fleas

There are thousands of species of fleas, with *Ctenocephalides felis felis* being the most common species in both dogs and cats.² Fleas have laterally compressed bodies and are 2 to 3 mm in length with a red-brown appearance and 3 pairs of legs (FIGURE 2).^{1,2} Predilection sites include the caudal dorsum, rump, and inguinal regions; however, fleas can be found anywhere on the body.

Fleas can transmit disease and are the intermediate host for the tapeworm *D caninum* and are vectors for *Rickettsia felis*, *Rickettsia typhi*, *Bartonella henselae*, *Bartonella clarridgeiae*, and *Mycoplasma* species.

All in-contact animals need treatment and environmental measures are often required.



FIGURE 2. Adult flea, *Ctenocephalides felis felis*. Magnification, 10×.

Surface-Dwelling Mites

***Cheyletiella* Species**

Infection with the mites *Cheyletiella yasguri* (dog) (FIGURE 3) and *Cheyletiella blakei* (cat) is referred to as cheyletiellosis. Movement of these mites can be seen in the diffuse scaling, and the term “walking dandruff” is used to describe this infestation.²

- **Physical characteristics:** These mites are larger than scabies mites and have some characteristics that are helpful in identification, such as 4 pairs of long legs that end in combs and mouth parts that have prominent hooks on both sides.
- **Predilection sites:** Predilection sites for dogs include the back and head but may be generalized.³ The face is the predilection site for cats, but distribution can also be generalized.³

Cheyletiella are highly contagious to dogs, cats, humans, and rabbits; therefore, the veterinary nurse should ask the client if there are any other affected animals or humans in the household.² All in-contact animals will need treatment.

Otodectes cynotis

O cynotis affects both dogs and cats as well as a number of other small mammals. These mites feed on epidermal debris and tissue fluid in the ear and cause ear canal irritation, resulting in cerumen, blood, and mite debris that has a “coffee-ground” appearance in the ear.²

- **Physical characteristics:** 0.4 to 0.5 mm in length; a tapered-to-a-point head; 4 pairs of long legs that end in cup-shaped suckers (males have suckers on all legs, females only have suckers on the 4 front legs)³




FIGURE 3. *Cheyletiella yasguri* with 1 prominent mouth hook showing. Magnification, 10×.



Ear Mite Sampling Materials

There are multiple ways to collect material from the external ear canal for microscopic examination, including cotton buds (being careful not to push debris deeper into the canal), curettes, ear loops, spatulas, and forceps. Other materials needed include:

- Dull #10 blade
- Mineral oil
- Microscope

Ear Mite Sampling Technique

1. Collect the samples with care in unsedated animals as sudden movements could cause injury to the ear canal.
2. Apply the debris to a slide with mineral oil.
3. Break up the crust using a dull #10 blade or other instrument of choice.
4. Examine the sample with the 4× and 10× objective lenses with the condenser down.

The ear mites live in the crust, which is why breaking up the debris in mineral oil will increase the likelihood of finding these mites under the microscope.

SUPERFICIAL SKIN SCRAPINGS

Superficial skin scrapings are useful in collecting the surface-dwelling mites (*Cheyletiella* species and *O. cynotis*) as well as the burrowing mites *Sarcoptes scabiei* and *Notoedres cati*.

Materials

- Dull #10 or #20 scalpel blade or scraping spatula
- Mineral oil
- Microscope slides
- Coverslip (if desired)
- Microscope

Technique

1. Clip or cut the hair with scissors (if needed), but do not disrupt the skin surface or any debris if noted.
2. Apply mineral oil to the region on the animal or to the blade or spatula before collecting the sample as this allows for adherence of the debris to the collection tool.
3. Place 1 to 2 drops of mineral oil on a slide.
4. Scrape the blade or spatula against the skin in a wide area multiple times, then use the blade to scoop up the debris and transfer it to the slide.

5. Spread out the debris on the slide to avoid clumped areas, then examine the debris with the 4× and 10× objective lenses with the condenser down.

Burrowing Mites

Sarcoptes scabiei

S. scabiei is a burrowing mite that lives in the stratum corneum, which is the skin's outermost layer (**FIGURE 4**). The mites are often few in number; therefore, false-negative scrapings can occur. Negative samples do not rule out this disease, and if scabies is suspected based on history and clinical signs, a treatment trial is recommended. Because these mites may be difficult to find, multiple scrapings (4 to 5) of any crusted, papular, or alopecic areas should be obtained. Look for areas with thick, honey-colored crusts to collect samples from, and avoid excoriated areas. The scraping is diagnostic if at least 1 mite, egg, or fecal pellet is found.

- Requires a microscope to visualize
- **Adult female size:** 0.3 to 0.6 mm long and 0.1 to 0.2 mm wide³
- **Adult male size (smaller than females):** Up to 0.3 mm long and 0.1 to 0.2 mm wide³
- **Physical characteristics:** Round, ventrally flattened bodies with a half-circle rounded head; adults have 4 pairs of legs (2 in the front that end in suckers and 2 in the back that end in long bristles)
- **Predilection sites:** Thinly haired areas, such as the ear margins, face, muzzle, elbows, and hocks

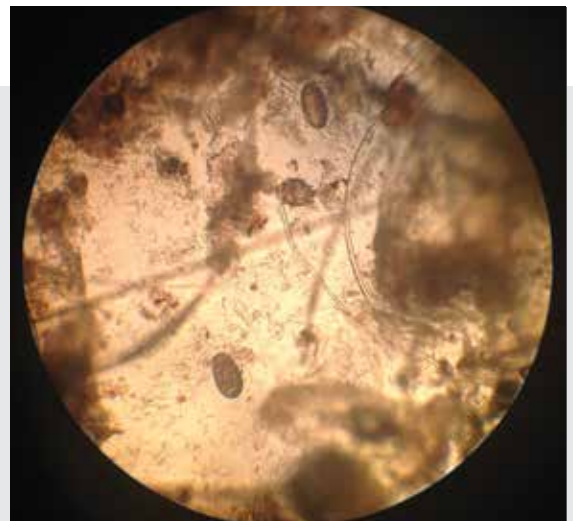

FIGURE 4. *Sarcoptes scabiei*.



- Highly contagious to dogs and cats; will bite humans, causing a papular rash particularly on the waist line and wrists
- Treatment required for all in-contact animals
- Cannot complete life cycle on human skin; therefore, treating the affected animals will be curative
- Wild animals such as foxes can carry scabies and be a source of infection for dogs and cats.

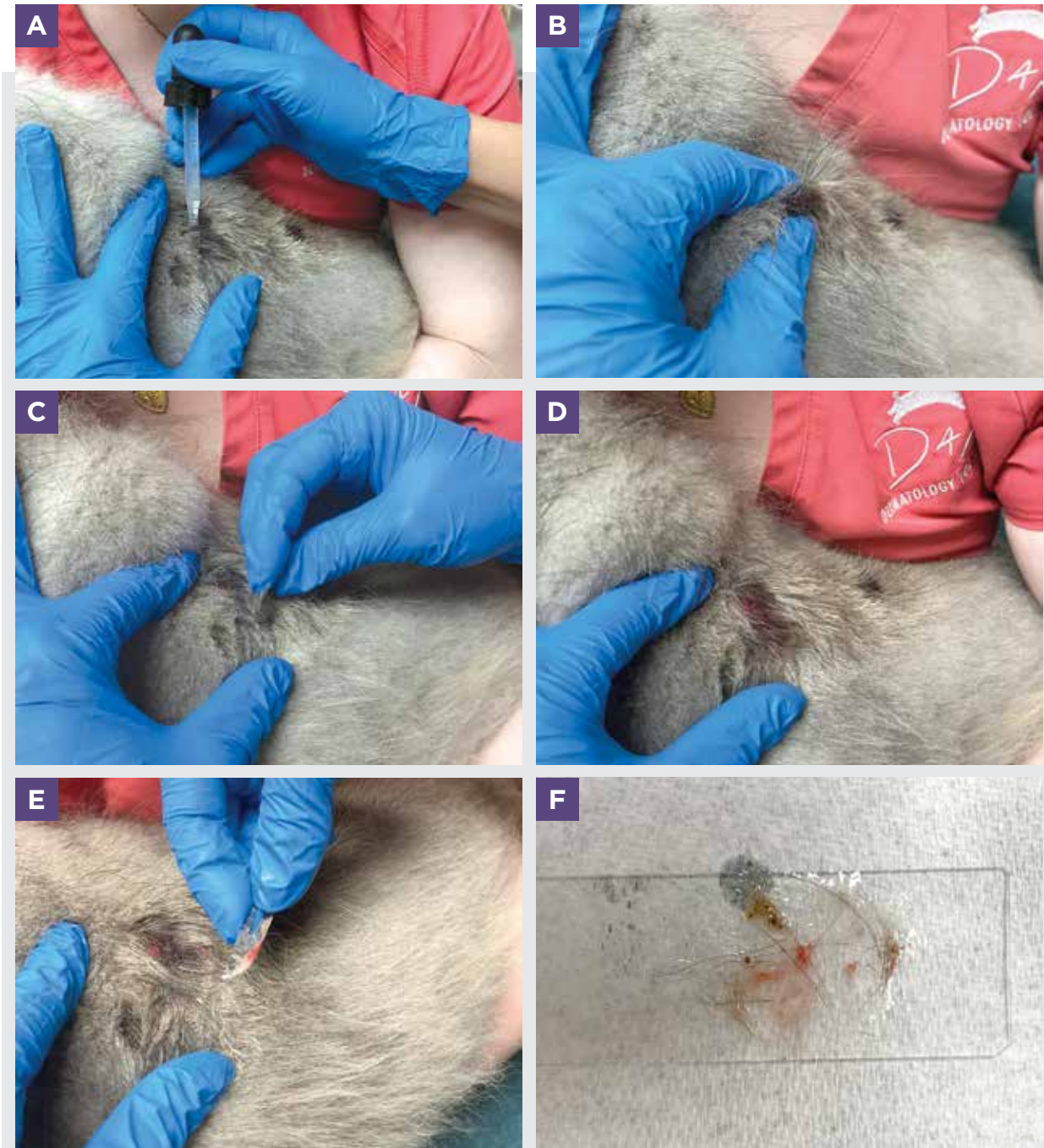


FIGURE 5. (A) A drop of mineral oil is placed on the area of the skin to be sampled. (B) The skin is pinched to help force the mites to the surface. (C) The skin is held taut between the thumb and index finger (left hand). The area is scraped with a dulled #10 blade in the direction of the hair growth while applying gentle downward pressure repeatedly until capillary bleeding is noted (right hand). (D) Due to capillary bleeding, a red rash forms at the scraped area. (E) The scraped material is scooped onto the blade to be transferred to a microscope slide. (F) The material is transferred to a microscope slide that had been prepped with a drop of mineral oil.



Notoedres cati

N cati not only burrows in the stratum corneum and stratum germinativum but will occasionally invade hair follicles and sebaceous glands, causing thickening of the epidermis and hyperkeratosis.³ These mites mainly affect cats but can also be contagious to dogs, rabbits, and foxes; all in-contact animals require treatment.²

- **Predilection sites:** The ear margins, face, eyelids, and neck. The skin can look wrinkled and folded with yellow to gray crusting present.
- **Physical characteristics:** *N cati* looks very similar to *S scabiei*; however, *N cati* mites are smaller in size and have a dorsal anus, which is a distinctive feature compared to the terminal anus of *S scabiei*.
- Easier to find on skin scrapings than *S scabiei* due to larger number of mites found on affected animals
- Use 10× objective lens with reduced light due to the small mite size and less visibility with intense light

DEEP SKIN SCRAPINGS

Deep skin scrapings are frequently performed and beneficial in ruling out and diagnosing demodicosis. Because *Demodex* mites live in the hair follicle and sebaceous glands, scraping down to the dermis is required. You will know when you have scraped deep enough once capillary bleeding occurs. The hair can be clipped if needed; however, be careful not to disrupt any skin debris or the skin surface itself.

Materials

A dulled #10 or #20 blade works well because of the curvature of these blades, which not only allows for scooping up the sample easily but also helps minimize the risk of tearing or cutting the skin. A #15 blade is smaller and can be used for areas such as the paws and ears. Skin scraping spatulas can also be used instead of blades and are blunter than scalpel blades. Mineral oil, microscope slides, coverslips (if desired), and a microscope are needed.

Technique

1. Place 1 drop of mineral oil on a microscope slide and set aside. Place 1 drop of mineral oil directly on the area to be scraped on the skin (**FIGURE 5A**).
2. Pinch the skin to help force the mites to the surface (**FIGURE 5B**).
3. Hold the skin taut to provide a flat surface and avoid bunching of the skin, and then scrape in the direction of the hair growth, applying gentle

downward pressure repeatedly (**FIGURE 5C**) until a red rash is formed (**FIGURE 5D**) and a small amount of blood is collected with the debris. (Avoid excessive blood in the sample as this will make it more difficult to find the mites.)

4. Scoop up the collected material and transfer to the microscope slide (**FIGURE 5E**). Spread out the debris on the slide to avoid overclumping (**FIGURE 5F**).
5. Examine with the 4× and 10× objective lens with the condenser down.

See **BOX 2** for additional tips.

Demodex

Demodex species are part of the normal fauna of the skin and is a commensal mite that can overpopulate and cause infections for a variety of reasons that are beyond the scope of this article. *Demodex* mites in dogs (*Demodex canis*, *Demodex injai*, and *Demodex cornei*) as well as *Demodex cati* in cats are noncontagious; however, the feline mite *Demodex gatoi* is contagious among cats, can cause intense pruritus, inhabits the superficial stratum corneum, and can be found with a superficial skin scrape.

***Demodex canis* (FIGURE 6)**

- **Physical characteristics:** 0.1 to 0.2 mm in length; elongated, “cigar-shaped” body; spindle-shaped eggs²
 - **Larvae:** 3 sets of stubby legs
 - **Nymphs:** 4 sets of stubby legs with no chest plates
 - **Adults:** 4 sets of stubby legs with prominent chest plates

BOX 2

Tips for Deep Skin Scrapings

- Warning clients that deep skin scrapings will create red, “rashy” areas on their pet before performing this diagnostic test is recommended.
- The squeeze tape technique can be used in place of deep skin scraping when the situation requires less invasiveness.
- Trichograms are another option to find *Demodex* mites.



- **Site selection:** Due to hair follicle plugging, comedones are frequent and a primary lesion and the best place to collect samples; other lesions include well-circumscribed areas of alopecia and erythematous/scaly lesions.
- **Predilection sites:** Face and forelimbs are common in the early stage of disease but can progress to be generalized.
- *D canis* is the most common of the *Demodex* mites.

Demodex injai (FIGURE 7)

- **Physical characteristics:** 0.3 to 0.4 mm in length; longer than *D canis*; elongated, “cigar-shaped” body²
- **Predilection sites:** Causes greasy, erythematous, and seborrheic skin, most commonly on the face and dorsum

Demodex cornei

- **Physical characteristics:** 0.1 to 0.15 mm in length; shorter and broader than *D canis* and *D injai*²
- Least common of the *Demodex* species

Demodex cati (FIGURE 8)

- **Physical characteristics:** 0.1 to 0.4 mm in length; elongated, “cigar-shaped” body³

- **Predilection sites:** Eyelids, periocular region, head, and neck; however, can be generalized²
- Usually associated with underlying disease, such as feline leukemia virus, feline immunodeficiency virus, diabetes mellitus, systemic lupus erythematosus, hypercortisolism, and squamous cell carcinoma in situ²

Demodex gatoi (FIGURE 9)

- **Physical characteristics:** 0.09 to 0.11 mm in length (use 10× objective lens to view these smaller mites); short, broad body
- **Predilection sites:** lateral thorax, ventral and lateral abdomen, and medial aspects of all 4 legs²

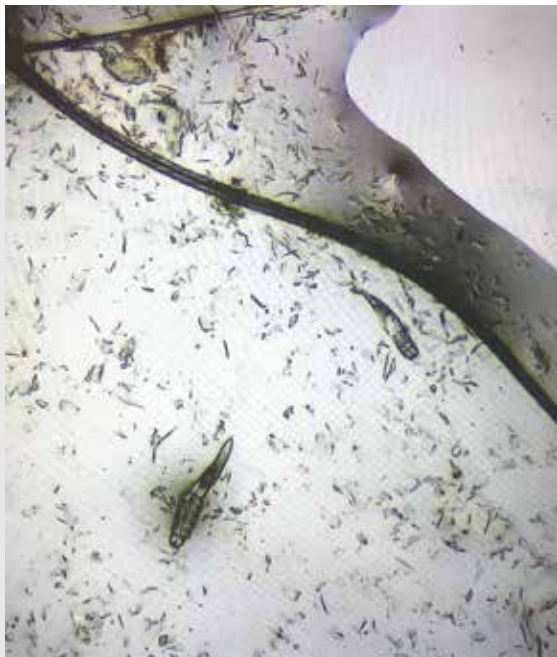

FIGURE 6. Adult *Demodex canis* mites. Magnification, 10×.

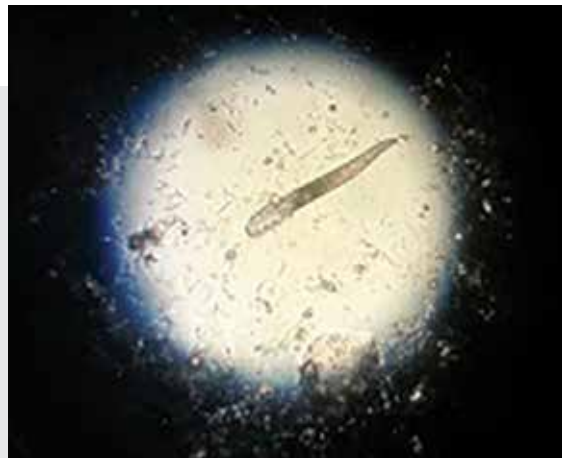

FIGURE 7. *Demodex injai*.

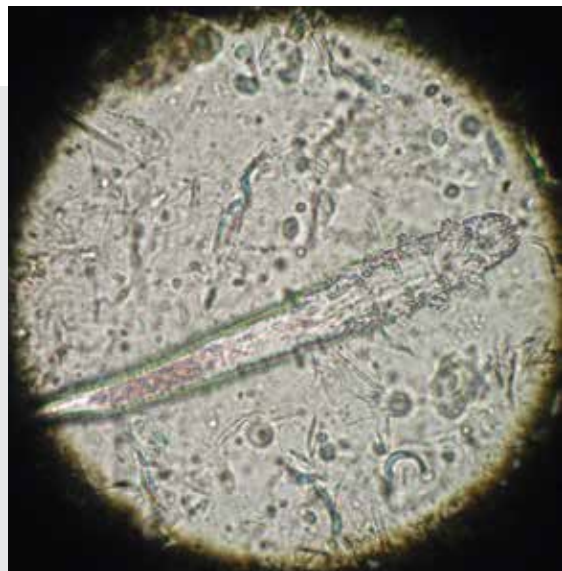

FIGURE 8. *Demodex cati*.

KNOW THE BOND.



**Human
Animal
Bond
Certified**

This course was designed in partnership with the Human-Animal Bond Research Institute to help explain what the bond is, how it works, and to demonstrate the role veterinary professionals play in supporting and strengthening its effects.

Your work means more than you know.

NAVC Certifications are available exclusively through VetFolio. Get certified today at vetfolio.com/pages/certifications.

GROW THE BOND.

NAVC
YOUR VETERINARY CERTIFICATIONS



PESTS AND PARASITES • PEER REVIEWED

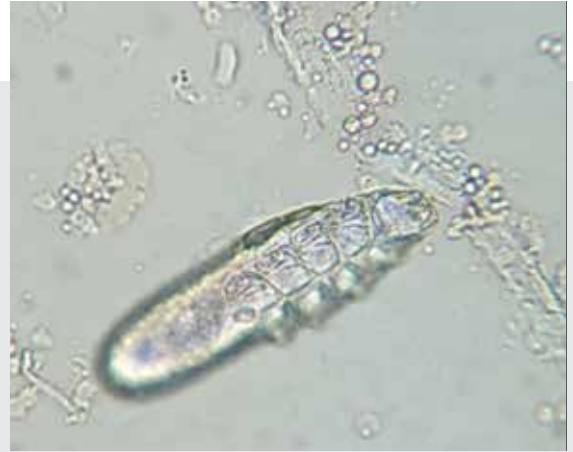

FIGURE 9. *Demodex gatoi*.

Figure 9: courtesy Selene Jones, DVM, DACVD

SUMMARY

Skin scraping and other sampling techniques for ectoparasites are simple diagnostics that should be performed with any patients presenting with skin disease. These tests yield immediate information and assist in getting to a diagnosis more quickly. The veterinary nurse not only communicates with clients about sample acquisition and what the veterinarian is looking for, but can also assist with efficiency of the practice by performing sample collection and microscopic evaluation for parasites. **TVN**

References

1. Neuber A, Nuttall T. Looking for parasites. In: *Diagnostic Techniques in Veterinary Dermatology*. Wiley-Blackwell; 2017:21-40.
2. Parasitic skin disease. In: Miller WH, Griffin CE, Campbell KL, eds. *Muller & Kirk's Small Animal Dermatology*. 7th ed. Saunders; 2013:284-342.
3. Taylor MA, Coop RL, Wall RL. Parasites of dogs and cats. In: *Veterinary Parasitology*. 4th ed. Wiley; 2016:599-677.



Shilo Anderson

Shilo started her career in general practice in 2000. In 2001, Shilo started working at a specialty clinic with the ophthalmology and dermatology services. In 2005, she became a licensed veterinary technician. In 2017, she received her veterinary technician specialty certification in dermatology. She is currently the practice leader for the Dermatology for Animals Salt Lake City, Utah, and Liberty Lake, Washington, locations.