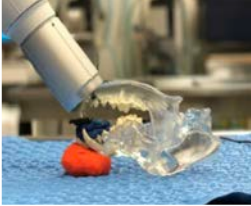
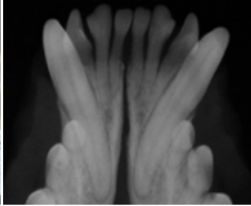
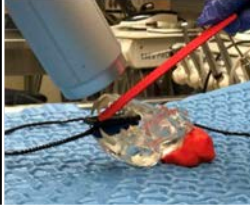
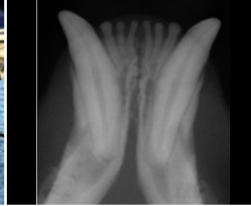
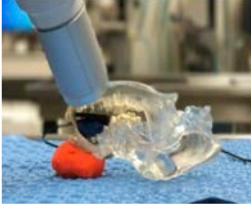

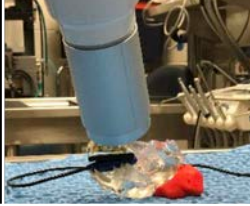
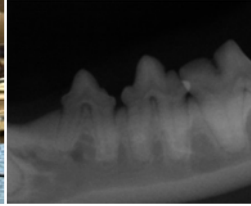



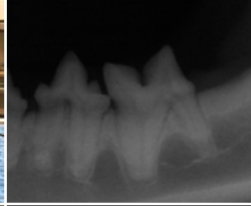
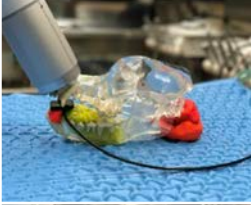








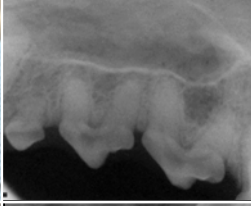




# Radiography Chart

VIEW	PATIENT RECUMBENCY	FILM/SENSOR PLACEMENT	TECHNIQUE	TIPS
<b>Rostral Mandibular</b> <i>Incisors/canines</i>	Dorsal	Parallel to mandible Edge of film to crowns length going caudally	Bisecting angle	Beam angle 15-25°
<b>Cranial Right/Left mandibular</b> <i>P1-p3</i>	Dorsal	Parallel to mandible Edge of film to crowns	Bisecting angle	Beam angle 30-45°
<b>Caudal</b> <b>Right/Left mandibular</b> <i>P3-m1</i>	Lateral-affect side up	Parallel to tooth On lingual surface of mandible	Parallel	Beam angle 90° to film
<b>Rostral maxillary</b> <i>Incisors/canines</i>	Sternal	Parallel to hard palate Edge of film to crowns length going caudally	Bisecting angle	Beam angle 45°
<b>Individual</b> <i>Canine tooth oblique</i>	Sternal-maxillary Dorsal-mandibular	Parallel to mandible or maxilla	Bisecting angle	Beam angle 30-45°
<b>Cranial Right/left Maxillary</b> <i>P1-p3</i>	Sternal	Parallel to hard palate	Bisecting angle	Beam angle 30-45°
<b>Caudal Right/Left Maxillary</b> <i>P3-m3</i>	Sternal	Parallel to hard palate	Bisecting angle	Beam angle 45° towards the lateral canthus

# Radiography Chart *continued*

VIEW	CANINE POSITIONING	RADIOGRAPH	FELINE POSITIONING	RADIOGRAPH
Rostral Mandibular <i>Incisors/canines</i>				
Cranial Right/Left mandibular <i>m2-m3</i>				
Caudal Right/Left mandibular <i>P3-m1</i>				
Rostral maxillary <i>Incisors/canines</i>				
Individual <i>Canine tooth oblique</i>				
Cranial Right/left Maxillary <i>P1-p3</i>				
Caudal Right/Left Maxillary <i>P3-m3</i>	